

# A Proprietary Topical Preparation Containing EGCG-Stearate and Glycerin with Inhibitory Effects on Herpes Simplex Virus: Case Study

Man Zhao<sup>1</sup>, Jinyan Jiang<sup>1</sup>, Rongrong Zheng<sup>1</sup>, Henna Pearl<sup>2</sup>, Douglas Dickinson<sup>3</sup>, Baiping Fu<sup>1</sup> and Stephen Hsu<sup>\*,3</sup>

<sup>1</sup>Department of General Dentistry, School of Stomatology Hospital, Zhejiang University, Hangzhou, China

<sup>2</sup>Department of Dermatology, Medical College of Georgia, USA

<sup>3</sup>Department of Oral Biology, College of Dental Medicine, Georgia Health Sciences University, Augusta, Georgia, USA

**Abstract:** The effects of a proprietary topical formulation containing EGCG-stearate in 100% glycerin USP were studied in two volunteer patients with recurrent herpes simplex (HSV) type 1. Application during early onset (prodromal stage) in a patient with herpes labialis prevented lesion progression. In a second patient with herpetic stomatitis, application of the formula during a later stage (inflammation stage) led to a remarkably shortened duration of symptoms. In contrast, a third patient provided 100% glycerin USP only as placebo failed to demonstrate any therapeutic or preventive effect against lesion occurrence or duration of lesion and healing time. These results suggest that this proprietary topical preparation could be used effectively to prevent and treat HSV-induced symptoms, and warrants further clinical investigation.

**Keywords:** Cold sore, green tea polyphenol, herpes labialis, herpes simplex virus, herpes stomatitis.

## INTRODUCTION

Green tea polyphenols, especially epigallocatechin-3-gallate (EGCG), have been reported to possess anti-viral properties [1-7]. EGCG has anti-HSV activity, showing significant inhibitory effect against HSV-1, and a remarkably high potency against HSV-2 [8]. However, the relative chemical instability of EGCG, a strong antioxidant, and its insolubility in lipid-based formulations pose challenges to its use as a topical applicant in patients with HSV infection [9-11]. Recently, an *in vitro* study using EGCG-palmitate showed this EGCG-acyl ester was nearly 10 times more potent against HSV type 1 than EGCG (De Oliveira *et al.*, manuscript under review, Life Sciences). The current study examined the clinical benefits of a proprietary topical application containing EGCG-stearate and 100% glycerin USP (referred to as "F2" hereafter, Camellix, LLC, Augusta, GA, USA) versus 100% glycerin USP as placebo in a small open label case study.

## METHODS

### Patient Selection

The protocol was approved by the Research Ethics Committee (equivalent to an Institutional Review Board in the US system) of the School of Stomatology/Hospital, Zhejiang University. After informed consent, adult patients (18 or older) were provided with a patient consent form, and the form was signed prior to the open-labeled study performed according to the Declaration of Helsinki.

Three patients were recruited and provided with instructions that directed them to the General Dentistry clinic immediately after signs of a breakout appeared. The patients were also provided with a self evaluation form with symptoms range from 0 (no symptom) to 5 (severe). The patients revisited the clinic daily at the same time each day until the primary dentist informed the patient his/her treatment was completed. Two subjects (patient #1 and patient #2) were provided with F2 topical application and the third (patient #3) was provided with 100% glycerin, along with instructions for their use. The lesional areas were self-photographed and topical applications were immediately applied after the first clinic visit (designated as Day 0).

### Patients and HSV History

Patient #1 was a 27 year old female with a history of recurrent oral mucosal manifestation that typically lasted for 7 days. Her recurrence rate is about two episodes per year, reportedly caused by stress or sickness. Patient #2 was a 32 year old male with a history of herpes labialis on the upper right lip with a typical duration of 16 days. The patient stated his annual occurrence is two episodes each year, caused by stress. Patient #3 was a 29 years old female with multiple recurrence of herpes labialis (5 episodes per year). All patients provided self-detected symptoms of previous episodes and the current episode (Table 1). At day 0, prior to topical application of F2 or glycerin, a clinic examination was performed (Table 1B). At day 1, 24 h after topical application, and daily thereafter until the lesions had cleared, clinical evaluations were performed on each patient

## RESULTS

None of the patients had used F2 prior to the study. Patient #1 listed pain (4/5) and heat (3/5) as the usual main symptoms, followed by swelling (2/5), tightness (2/5), itchiness (1/5) and psychological stress (1/5). Patient#1

\*Address correspondence to this author at the AD1443 College of Dental Medicine, Georgia Health Sciences University, 1120 15th Street, Augusta, GA 30912, USA; Tel: 1-706-721-4816; Fax: 1-706-721-3392; E-mail: shsu@georgiahealth.edu

Table 1.

## (A). Self Detected Symptoms During Previous Episodes

Patient/Score	Itchiness	Pain	Heat	Swollen	Tightness	Bleeding	Psychological Stress
1	1	4	3	2	2	0	1
2	0	2	1	1	2	0	1
3	2	2	2	2	2	2	1

## (B). Current Episode Symptoms During the First Clinic Visit (Day 0)

Patient	Itchiness	Pain	Heat	Swollen	Tightness	Bleeding	Psychological Stress	Lesion Size	Stage
1	1	4	3	2	2	0	1	Diffused	Vesicle
2	0	0	1	0	3	0	0	0.8x0.5	Prodromal
3	2	0	0	0	0	0	0	1x0.6	Vesicle

presented for her first clinic visit prior to using F2 (day 0) 24 hrs after detecting an outbreak in association with a common cold. She described her symptoms with the same values as previous outbreaks. Clinically, she was at the inflammation stage, with red macules on the upper and lower buccal mucosa and vesicles on the left-lower lip, (Fig. 1A, B, Table 1).

When examined during the second clinic visit (day 1 of F2 application) after 8 self-topical applications of F2 within a 24 h period, Patient #1 had mild erythema on the upper and lower buccal mucosa, with diminishing vesicles on the left-lower lip (Fig. 1C, D). By day 2 of F2 application, minimal appreciable erythema on labial mucosa was observed (Fig. 1E, F). At day 3 (4<sup>th</sup> and final clinic visit), there was no appreciable erythema on labial mucosa. Patient #1 was considered completely healed with no lesions after three days of F2 application (Fig. 1G, H). She also denied any symptoms at day 2 and day 3. Thus, this patient avoided any noticeable vesicles or ulcers. She did not report any adverse effects. Patient #1 was informed that her treatment was completed after the fifth clinic visit (day 4), and F2 application was discontinued.

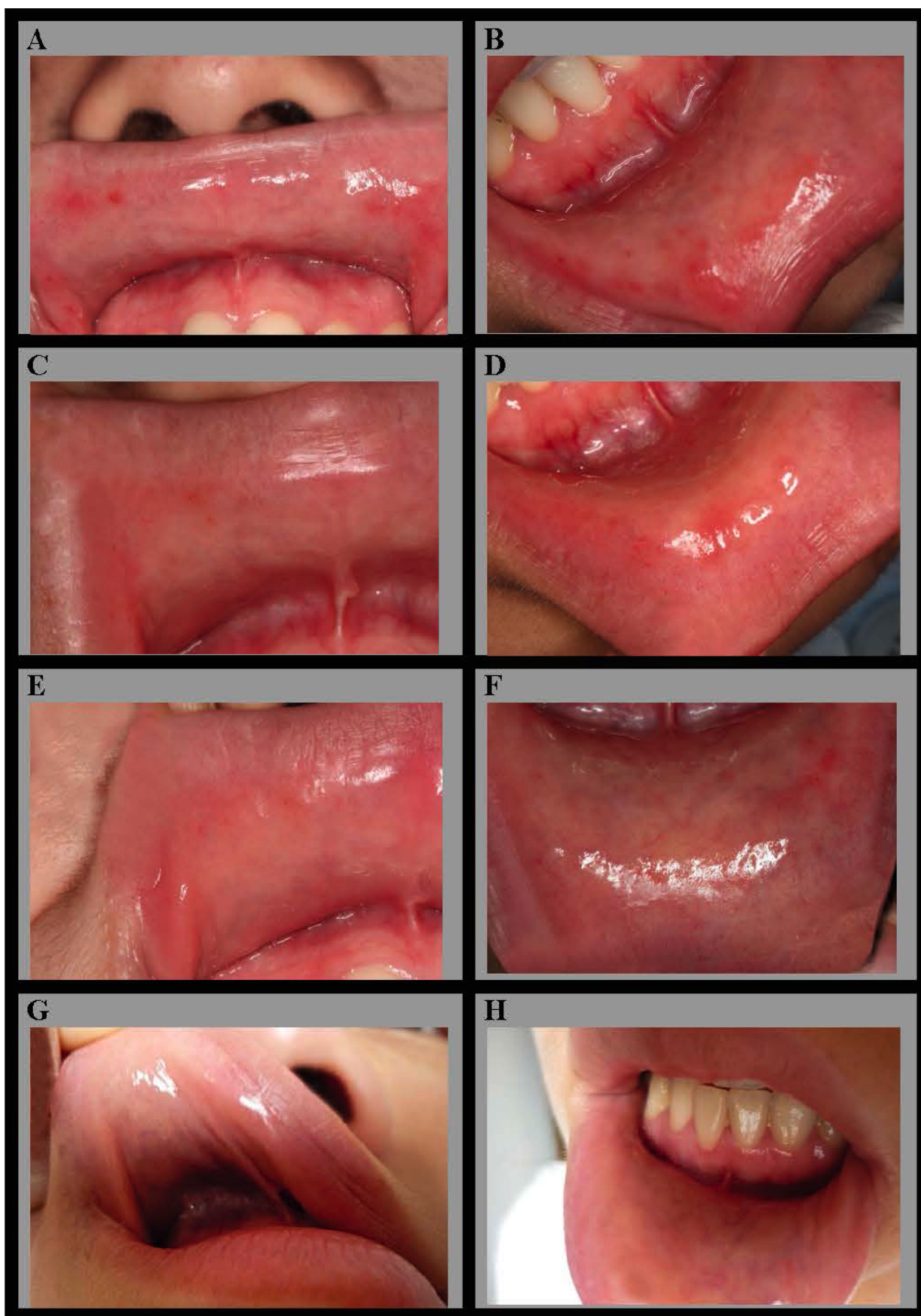
Patient #2 described his typical symptoms as pain (2/5), tightness (2/5), heat, swelling and psychological stress (1/5). On day 0 (0.5 hr after outbreak noticed), he presented with a pink, erythematous 0.5 x 0.8 cm macule on the upper right cutaneous and mucosal lip (Fig. 2A), and was therefore at the prodromal stage. He described his symptoms at presentation as tightness (3/5) and heat (1/5). Patient #2 applied F2 6 times during the next 24 hrs. When Patient #2 was examined during the second clinic visit (day 1), there was no appreciable erythema on the upper cutaneous and mucosal lip (Fig. 2B). The patient was informed that his treatment was completed after the second clinic visit (day 1) and F2 application was discontinued.

Patient #3 listed her typical symptoms as pain, heat, itchiness, swelling, tightness and bleeding (all scored 2/5), and psychological stress (1/5). On day 0 (0.5 hr after outbreak), she

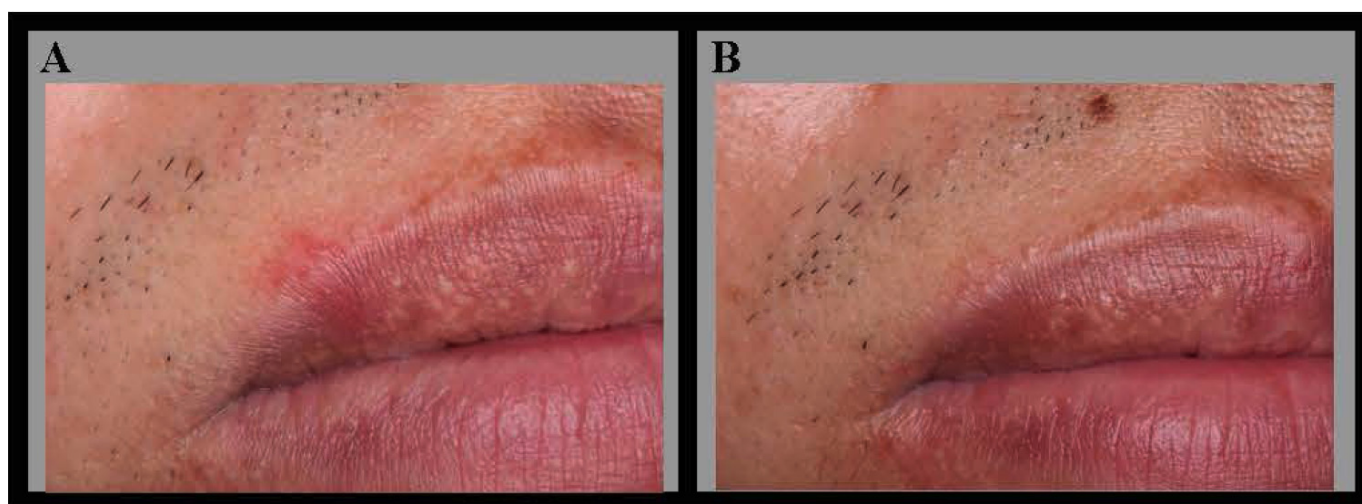
presented with a 1 x 0.6 cm area of erythematous macules with pinpoint vesicles on the lower cutaneous and mucosal lip (Fig. 3A), in association with self-described emotional causes, and a symptom of itchiness (2/5); they were at the blister stage. Patient #3 initiated topical application of vehicle (100% glycerin) immediately after the day 0 clinic visit. By day1, multiple small erythematous vesicles had erupted on the lower lip (Fig. 3B). On day 2, symptoms had continued to progress with multiple vesicles with an erythematous base, and a few crusted vesicles (Fig. 3C). On day 3, multiple red ulcers with overlying hemorrhagic crust were documented (Fig. 3D). After 4 days of vehicle application (day 4), multiple red ulcers with overlying hemorrhagic crust were present (Fig. 3E). Day 5 examination showed healing erosions, and a few crusted ulcers (Fig. 3F). By day 6, a few healing erosions on a pink base and mild bleeding were observed (Fig. 3G). By day 7, small healing erosions still existed (Fig. 3H). These results indicate that for Patient #3 (used the inactive vehicle only), the episode was not shortened and the lesions progressed through the prodromal stage, and developed into crusted vesicles, ulcers and erosions. At Day 7, the patient was healing, but lesions were still visible. Patient #3 discontinued vehicle (glycerin) application after the eighth clinic visit (day 7), when healing was not completed. Patient #3 would be expected to heal in an additional 3-4 days, which would be consistent with her typical episode duration (7-10 days).

## DISCUSSION

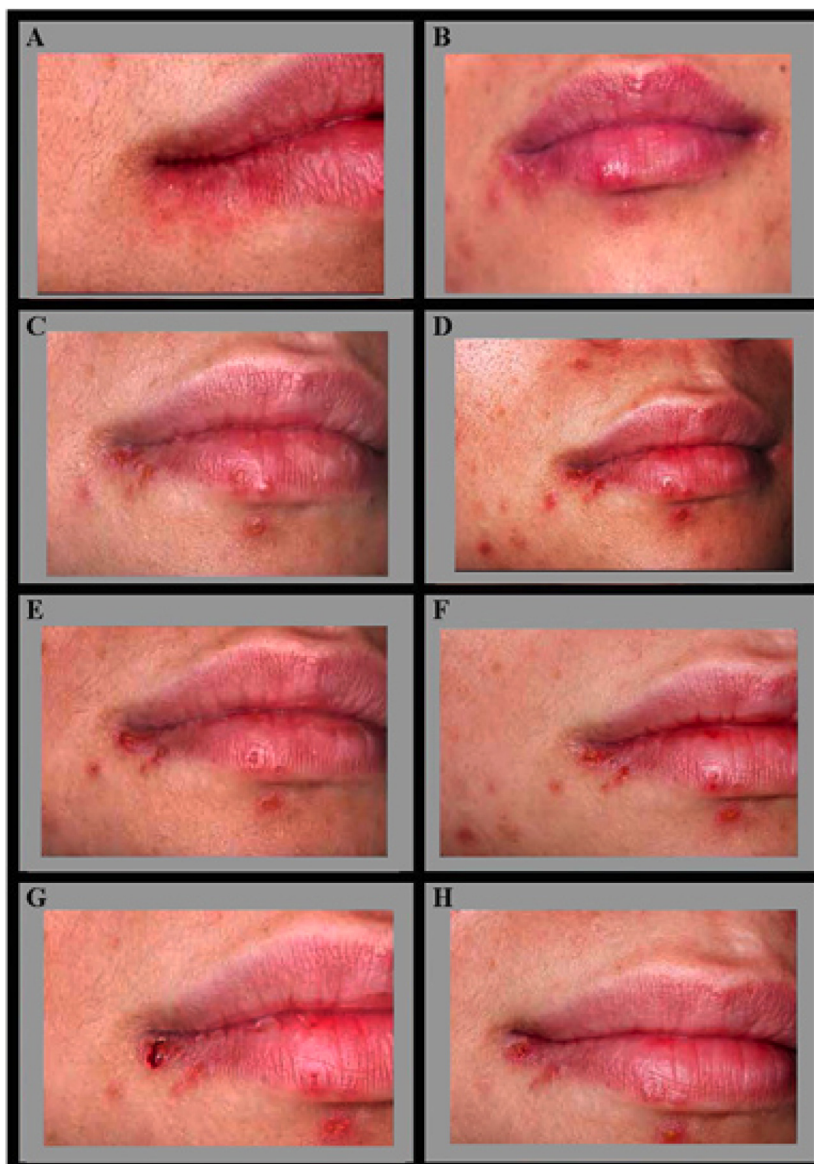The results from Patient #1 demonstrated that application of F2 at the inflammation stage appeared to effectively inhibited vesicle formation, erythema, and inflammation within a 48 h period; the patient was symptom free after application of F2 for 72 h. This indicates that F2 topical application significantly shortened the duration of the patient's typical episode time, from 7 days to 4 days, with significantly milder symptoms, and without typical vesicle and ulceration stages. For Patient#2, the application of F2 for one day at the prodromal stage prevented the eruption of vesicles, and without any further self-detected symptoms developing. Thus the episode was arrested at the prodromal



**Fig. (1).** Photographs of upper and lower lips of patient #1 at first clinic visit (**A, B**); second clinic visit: 24 h after the first visit, with F2 self applications (**C, D**); third clinic visit: 48 h after the first visit, with F2 self applications (**E, F**); and fourth clinic visit, 72 h after the first visit, with F2 self applications (**G, H**). Photos were taken by the patient in the clinic.



**Fig. (2).** Herpes labialis at prodromal stage (A) and 24 h after the first photograph was taken (B). The subject applied F2 6 times during the 24 h period, and after which the erythema diminished. Photos were taken by the patient in the clinic.



**Fig. (3).** Photographs of upper and lower lips of patient #3 at day 0 (A), day 1 (B), day 2 (C), day 3 (D), day 4 (E), day 5 (F), day 6 (G), and day 7 (H) treated with vehicle only. Photos were taken by the patient in the clinic.



stage, and did not continue for the 16 day-duration typical for this patient. For Patient#3, the results demonstrated that the vehicle did not possess any therapeutic effect, and the outbreak continued to progress and resolve as normal.

In conclusion, the current case study indicates that the proprietary formulation with EGCG-acyl ester (stearate) in glycerin has potential therapeutic effects in the prevention and treatment of oral herpes outbreaks. To the best of our knowledge, this is the first report describing a human study using an EGCG-acyl ester on herpes labialis/stomatitis. Due to the similarities among herpes simplex virus family members and previously reported *in vitro* data, we hypothesize that EGCG-acyl esters could be effective against genital herpes (HSV-2), shingles (varicella zoster virus), and other viral-induced symptoms as a preventive and therapeutic agent without a known side effect. Based on the results reported here, future clinical trials and development of therapeutic formulations are warranted.

## ACKNOWLEDGEMENT

The authors thank Dr. Loretta Davis for reading the manuscript and her valuable suggestions, and Mr. Philip Jones for graphic work. This study was supported in part by a grant from Georgia Research Alliance to SH.

## REFERENCES

- [1] Song, J.M.; Lee K.H.; Seong, B.L. Antiviral effect of catechins in green tea on influenza virus. *Antiviral Res.*, **2005**, *68*, 66-74.
- [2] Imanishi, N.; Tuji, Y.; Katada Y.; Maruhashi, M.; Konosu, S.; Mantani, N.; Terasawa, K.; Ochiai, H. Additional Inhibitory Effect of Tea Extract on the Growth of Influenza A and B Viruses in MDCK Cells. *Microbiol. Immunol.*, **2002**, *46*, 491-494.
- [3] Xu, J.; Wang, J.; Deng, F.; Hu, Z.; Wang, H. Green tea extract and its major component epigallocatechin gallate inhibits hepatitis B virus *in vitro*. *Antiviral Res.*, **2008**, *78*, 242-249.
- [4] Chang, L.K.; Wei, T.T.; Chiu, Y.F.; Tung, C.P.; Chuang, J.Y.; Hung, S.K.; Li, C.; Liu, S.T. Inhibition of Epstein-Barr virus lytic cycle by (-)-epigallocatechin gallate. *Biochem. Biophys. Res. Commun.*, **2003**, *301*, 1062-1068.
- [5] Weber, J.M.; Ruzindana-Umunyana, A.; Imbeault, L.; Sircar, S. Inhibition of adenovirus infection and adenain by green tea catechins. *Antiviral Res.*, **2003**, *58*, 167-173.
- [6] Fassina, G.; Buffa, A.; Benelli, R.; Varnier, O.E.; Noonan, D.M.; Albin, A. Polyphenolic antioxidant (-)-epigallocatechin-3-gallate from green tea as a candidate anti-HIV agent. *AIDS*, **2002**, *16*, 939-941.
- [7] Yamaguchi, K.; Honda, M.; Ikigai, H.; Hara, Y.; Shimamura, T. Inhibitory effects of (-)-epigallocatechin gallate on the life cycle of human immunodeficiency virus type 1 (HIV-1). *Antiviral Res.*, **2002**, *53*, 19-34.
- [8] Isaacs, C.E.; Wen, G.Y.; Xu, W.; Jia, J.H.; Rohan, L.; Corbo, C.; Di Maggio, V.; Jenkins, E.C. Jr.; Hillier, S. Epigallocatechin gallate inactivates clinical isolates of herpes simplex virus. *Antimicrob. Agents Chemother.*, **2008**, *52*, 962-970.
- [9] Hsu, S. Green Tea and the Skin. *J. Am. Acad. Dermatol.*, **2005**, *52*, 1049-1059.
- [10] Chen P.; Dickinson, D.; Hsu, S. Lipid-soluble green tea polyphenols: potentials for health care and consumer products. In: Helen McKinley and Mark Jamieson, eds. *Handbook of Green Tea and Health Research*. New York: Nova Publishers. **2009**, 45-61.
- [11] Hsu, S.; Dickinson, D. Green tea and skin protection: mechanism of action and practical applications. *Household and Personal Care*. **2009**; June 33-36.